

International Journal of Advanced Biochemistry Research



ISSN Print: 2617-4693
 ISSN Online: 2617-4707
 IJABR 2024; SP-8(4): 550-552
www.biochemjournal.com
 Received: 07-01-2024
 Accepted: 17-03-2024

AA Suryawanshi
 Department of Teaching
 Veterinary and Clinical
 Complex, Mumbai Veterinary
 College, Parel, Mumbai,
 Maharashtra, India

DA Pawalkar
 Department of Veterinary
 Epidemiology and Preventive
 Medicine, Mumbai Veterinary
 College, Parel, Mumbai,
 Maharashtra, India

RV Gaikwad
 Department of Veterinary
 Clinical Medicine, Ethics and
 Jurisprudence, Mumbai
 Veterinary College, Parel,
 Mumbai, Maharashtra, India

CN Galdhar
 Department of Veterinary
 Clinical Medicine, Ethics and
 Jurisprudence, Mumbai
 Veterinary College, Parel,
 Mumbai, Maharashtra, India

JU Patil
 Department of Veterinary
 Clinical Medicine, Ethics and
 Jurisprudence, Mumbai
 Veterinary College, Parel,
 Mumbai, Maharashtra, India

Corresponding Author:
AA Suryawanshi
 Department of Teaching
 Veterinary and Clinical
 Complex, Mumbai Veterinary
 College, Parel, Mumbai,
 Maharashtra, India

Haemato-biochemical study of Theileriosis in Satara and Solapur District of Maharashtra

AA Suryawanshi, DA Pawalkar, RV Gaikwad, CN Galdhar and JU Patil

DOI: <https://doi.org/10.33545/26174693.2024.v8.i4Sg.1077>

Abstract

The study was undertaken to know the haemato-biochemical alteration in blood smear positive and blood smear negative *Theileria* spp. in crossbred cows in Khandala, Phaltan, Lonand and Pandharpur taluka of Satara and Solapur district. 103 cross bred cattle selected randomly irrespective of age, breed, sex, physiological status, farming system etc. and blood samples were collected in EDTA and plain vials. Samples were screened for the presence of *Theileria* spp. schizonts by microscopy and further analysed to estimate haemato-biochemical parameters. There was 7/103 (6.79%) cattles were positive for *Theileria* spp. by microscopic examination of blood smear. Blood smear positive group showed statistically highly significant lymphocytosis ($p < 0.01$), while Blood smear negative group showed statistically highly significant neutrophilia ($p < 0.01$) (Table 1). Difference in monocyte count of these groups was also statistically significant ($p < 0.01$), however individual animal values of monocyte were within normal physiological limit in both the groups. Hb, PCV, TEC and TLC were relatively lower in blood smear positive animals but the difference was statistically non-significant. The finding suggestive of low-grade chronic infection (carrier state). Neutrophilia in blood smear negative animals was not reflected in TLC.

Keywords: Haemato-biochemical, theileriosis, blood smear

Introduction

India is an agricultural country in which livestock plays an important role. Livestock could be a source of supportive income for several families in India, particularly the poor who maintain some heads of animals. Haemoprotozoan infections mainly transmitted by tick and occasionally through blood transfusion (Salih *et al.*, 2015) [7]. Tick are also indirectly responsible for anaemia, hide damage and tick paralysis in animals. Haemoparasitic infested animals are usually anaemic, emaciated with poor productive and reproductive performances and reduced working capacity in draft animals. Clinical signs such as fever, in appetite, anemia, coughing, Dyspnea, reduced milk yield, swollen subcutaneous lymph nodes, neurological signs like incoordination particularly in weak animals, abortion, icterus, haemoglobinuria and soil licking, raise suspicion of clinical theileriosis, and pave way for confirmatory diagnosis whereas the animals with low infectivity remain undiagnosed and continue to be a constant source of infection for other susceptible hosts. (Sahoo *et al.*, 2017) [6].

Materials and Method

103 animals (cattle's) blood samples were collected and analysed from farmers in Satara and Solapur districts from September 2021 to February 2022 (6 months). Approximately 10 ml blood was collect aseptically from jugular veins in Ethylene Diamine Tetra Acetic Acid (EDTA) vials (4 ml) and plain vials (6 ml) respectively. The blood smears prepared on the spot were fixed using absolute methanol and stained with Giemsa stain (1: 10 ratio).

Results and Discussion

103 cross bred cattle selected randomly irrespective of age, breed, sex, physiological status, farming system etc. and blood samples were collected in EDTA and plain vials. Samples were screened for the presence of *Theileria* spp. Schizonts by microscopy and further analysed to estimate haemato-biochemical parameters (Fig.1).

There was 7/103 (6.79%) cattle's were positive for *Theileria spp.* by microscopic examination of blood smear. Similar findings were also reported by various workers. Shah *et al.*, (2020) [8] reported prevalence of Theileriosis 5.83% in Marathwada region in Maharashtra by blood smear examination. Jayalakshmi *et al.*, (2019) [3] reported overall 2.19% prevalence of *Theileria spp.* and higher prevalence 7.8% was recorded in summer months with blood smear examination in Tamil Nadu state of India. Khawale *et al.*, (2019) [4] reported Giemsa staining of blood smears of cattle revealed overall prevalence of theileriosis (22.38%) in Marathwada region of Maharashtra.

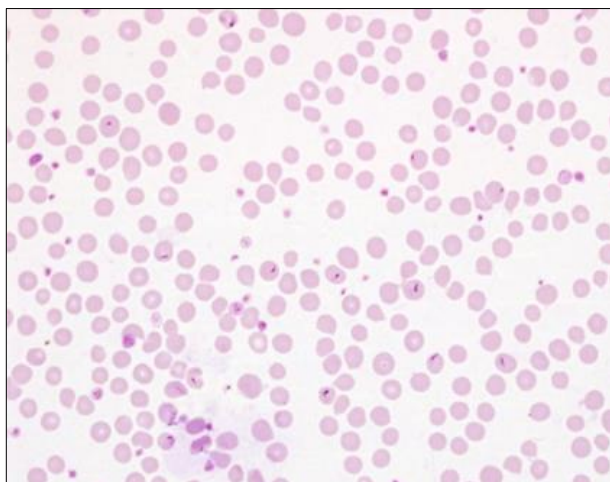


Fig 1: Giemsa staining (*Theileria spp.*)

Haemato-biochemical comparison of blood smear positive and blood smear negative animals

Blood smear positive group showed statistically highly significant lymphocytosis ($p < 0.01$), while Blood smear negative group showed statistically highly significant neutrophilia ($p < 0.01$) (Table 1). Difference in monocyte count of these groups was also statistically significant ($p < 0.01$), however individual animal values of monocyte were within normal physiological limit in both the groups.

Hb, PCV, TEC and TLC were relatively lower in blood smear positive animals but the difference was statistically non-significant. The finding suggestive of low-grade chronic infection (carrier state). Neutrophilia in blood smear negative animals was not reflected in TLC.

Findings are in agreement with Bhosale *et al.*, (2020) [1] reported haematological values of theileriosis affected animals were statistically low as compare to the healthy animals ($n=14$). They reported the values as follows, Hb 7.52 ± 0.40 g/dl, PCV $22.00 \pm 1.24\%$, TEC 3.71 ± 0.28 $10^6/\text{mm}^3$, TLC 10.51 ± 1.02 $10^6/\text{mm}^3$, Lymphocyte ($\times 10^3/\mu\text{l}$) 4.45 ± 0.48 , Monocyte ($\times 10^3/\mu\text{l}$) 0.37 ± 0.06 , Neutrophil ($\times 10^3/\mu\text{l}$) 5.66 ± 0.76 , PLT ($\times 10^3/\mu\text{l}$) 193.50 ± 16.65 . Brahmabhatt *et al.*, (2019) [2] studied clinico-haematological values of theileriosis in cattles ($n=64$). Haemato-biochemical values (mean \pm SD) were as follows Hb (g/dL) 7.45 ± 0.58 , PCV (%) 23.75 ± 0.09 , TEC (million/ μL) 4.34 ± 0.23 , TLC ($10^3/\mu\text{L}$) 9.76 ± 0.59 , Neutrophil (%) 60.50 ± 4.80 , Lymphocytes (%) 36.00 ± 5.11 , Monocytes (%) 2.75 ± 1.01 , Eosinophils (%) 1.25 ± 0.46 , Basophils (%) 0, Platelets ($10^5/\mu\text{L}$) 3.78 ± 0.46 .

Aspartate Transaminase of blood smear positive animals were higher than that of blood smear negative animals however the difference was statistically non-significant which may be due to chronic infection. Modi *et al.*, (2014) [5] reported that the biochemical values of theileriosis affected crossbred cattles. The mean \pm SD values as follows AST (IU/L) 124.74 ± 0.56 , ALT (IU/L) 42.38 ± 0.34 , Total Protein (g/dl) 4.94 ± 0.12 . Bhosale *et al.*, (2020) [1] reported that the biochemical findings in theileriosis affected animals ($n=14$) were found higher range of Total bilirubin (mg/dl) 1.76 ± 0.20 , Direct bilirubin (mg/dl) 1.07 ± 0.16 , Indirect bilirubin (mg/dl) 0.69 ± 0.08 , SGPT (U/L) 70.57 ± 4.13 respectively. Serum biochemical alterations in theileriosis affected crossbred cows revealed lowered total protein levels indicative of hypoproteinaemia. Serum creatinine and BUN levels did not alter significantly in cows with theileriosis. Increased levels of AST and ALT suggested possible involvement of hepatic tissues in disease progression among crossbred dairy cows.

Table 1: Haematological comparison of blood smear positive and blood smear negative animals

Parameter	Blood smear +ve (Mean \pm SD) (n=7)	Blood smear -ve (Mean \pm SD) (n=96)	Calculated 't'	Table 't' ($p < 0.05$, $p < 0.01$)
Hb (g/dL)	7.56 ± 1.86	7.76 ± 1.5	0.335 ^{NS}	1.96, 2.576
PCV (%)	24.23 ± 5.52	28.69 ± 7.88	1.47 ^{NS}	
TEC ($10^6/\text{mm}^3$)	4.81 ± 1.46	5.99 ± 1.88	1.617 ^{NS}	
TLC ($10^3/\text{mm}^3$)	8.65 ± 3.14	9.3 ± 2.91	0.576 ^{NS}	
Neutrophils (%)	27.57 ± 12.77	43.98 ± 11.31	3.676**	
Lymphocytes (%)	71.29 ± 12.66	55.63 ± 11.3	3.513**	
Monocytes (%)	1 ± 0	0.33 ± 0.52	3.4**	
Eosinophils (%)	0.14 ± 0.38	0.06 ± 0.28	0.708 ^{NS}	
Basophils (%)	0 ± 0	0 ± 0	0	
Plateletes (lac/ μl)	2.58 ± 2	2.23 ± 1.38	0.633 ^{NS}	
Total Bilirubin (mg/dl)	0.58 ± 0.27	0.65 ± 0.36	0.464 ^{NS}	1.96, 2.576
Direct Bilirubin (mg/dl)	0.07 ± 0.05	0.13 ± 0.1	1.625 ^{NS}	
Indirect Bilirubin (mg/dl)	0.51 ± 0.23	0.51 ± 0.32	0.022 ^{NS}	
Alkaline Phosphatase (IU/L)	153.15 ± 135.3	184.32 ± 132.88	0.893 ^{NS}	
Aspartate Transaminase (IU/L)	42.33 ± 16	33.21 ± 15.39	1.51 ^{NS}	
Alanine Transaminase (IU/L)	20.77 ± 4.49	23.58 ± 10.01	0.733 ^{NS}	
Total Proteins (gm/dl)	6.66 ± 1.42	6.77 ± 1.44	0.186 ^{NS}	
Albumin (gm/dl)	3.14 ± 1.95	3.38 ± 1.67	0.366 ^{NS}	
Globulin (gm/dl)	3.5 ± 0.58	3.36 ± 0.9	0.414 ^{NS}	
A/G Ratio	1 ± 0.75	1.43 ± 2.26	0.502 ^{NS}	

Conclusion

In this study of 103 randomly selected crossbred cattle, 6.79% were found positive for *Theileria* spp. infection via microscopic examination of blood smears. Significant haemato-biochemical differences were observed between blood smear positive and negative groups, with lymphocytosis in the former and neutrophilia in the latter. Although Hb, PCV, TEC, and TLC were relatively lower in blood smear positive animals, the differences were statistically non-significant, suggestive of a low-grade chronic infection. These findings align with previous research on Theileriosis, highlighting its impact on haemato-biochemical parameters. Elevated AST levels in blood smear positive animals suggest possible hepatic involvement. Overall, this study underscores the importance of surveillance and management strategies for *Theileria* spp. infection in crossbred cattle.

References

1. Bhosale AA, Bhikane AU, Chavhan SG, Jadhav RK, Mohan A, Kushwaha N. Prevalence and Clinico-Therapeutic Management of Bubaline Theileriosis in Marathwada Region of Maharashtra. *International Journal of Livestock Research*. 2020;10(9):155-165. <https://doi.org/10.5455/ijlr.20200608>
2. Brahmhatt NN, Kumar B, Thakre BJ, Parmar VL, Choravada DR, Patel JA. Clinico-haematological Study of Theileriosis in Gir and Jaffrabadi Calves. *The Indian Journal of Veterinary Sciences and Biotechnology*. 2019;14(4):36-39. <https://doi.org/10.21887/ijvsbt.14.4.10>
3. Jayalakshmi K, Sasikala M, Veeraselvam M, Venkatesan M, Yogeshpriya S, Ramkumar PK, *et al.* Prevalence of haemoprotozoan diseases in cattle of Cauvery delta region of Tamil Nadu. *Journal of Parasitic Diseases*. 2019;43(2):308-312. <https://doi.org/10.1007/s12639-019-01094-7>
4. Khawale TS, Siddiqui MF, Borikar ST, Sakhare MP, Rajurkar SR, Chigure GM, *et al.* Study of occurrence of theileriosis in cattle from Parbhani district, Maharashtra, India. *The Pharma Innovation Journal*. 2019;8(9):171-173.
5. Modi DV, Bhadesiya CM, Mandali GC. Serum Biochemistry Alterations in Theileriosis Affected Crossbred Cows in Banaskantha District of Gujarat. *International Journal of Novel Research in Healthcare and Nursing*. 2014;1(1):12-14. www.noveltyjournals.com
6. Sahoo N, Behera BK, Khuntia HK, Dash M. Prevalence of carrier state theileriosis in lactating cows. *Veterinary World*. 2017;10(12):1471-1474. <https://doi.org/10.14202/vetworld.2017.1471-1474>
7. Salih DA, El-Hussein AM, Singla LD. Diagnostic approaches for tick-borne haemoparasitic diseases in livestock. *Journal of Veterinary Medicine and Animal Health*. 2015;7(2):45-56. <https://doi.org/10.5897/jvmah2014.0345>
8. Shah N, Bhikane A, Chavhan S, Jadhav R, Kushwaha N. Epidemiological Investigations on Haemoprotozoan Infections in Cattle in Marathwada Region of Maharashtra. *International Journal of Livestock Research*. 2020;10(1):32-39. <https://doi.org/10.5455/ijlr.20191025063305>